ANAESTHESIA CONSIDERATION IN POSTERIOR FOSSA SURGERY

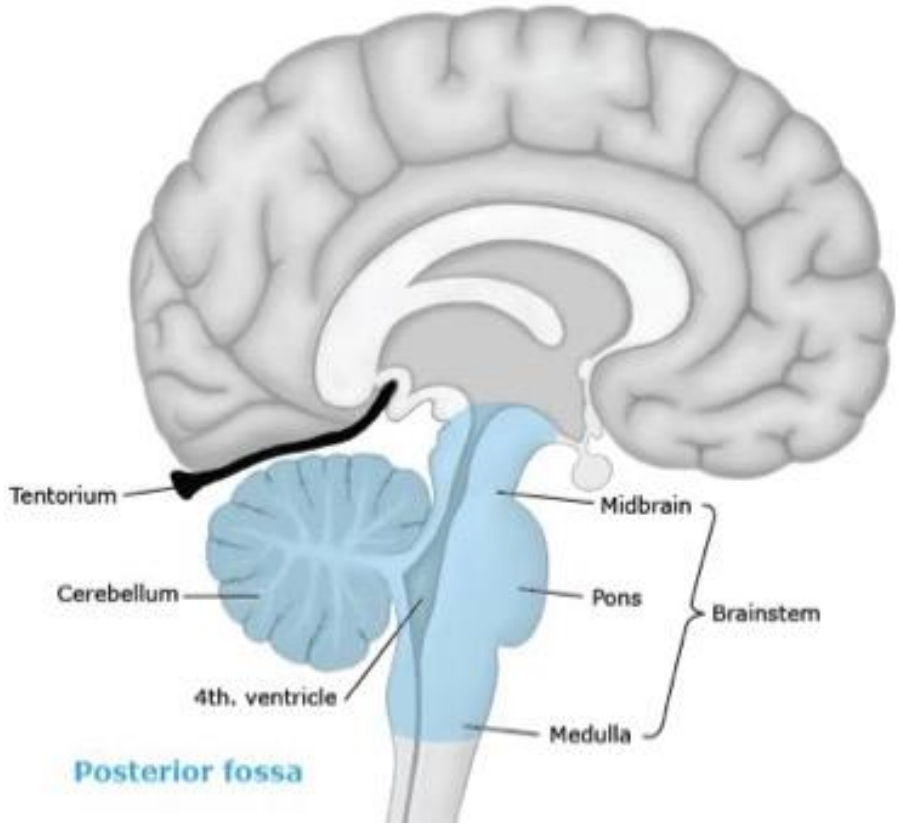
Tentorium
Cerebellum
4th. ventricle
Midbrain
Pons
Brainstem
Medulla
Posterior fossa

PRESENTER: DR SURBHI
MODERATOR:DR NARESH

POSTERIOR CRANIAL FOSSA

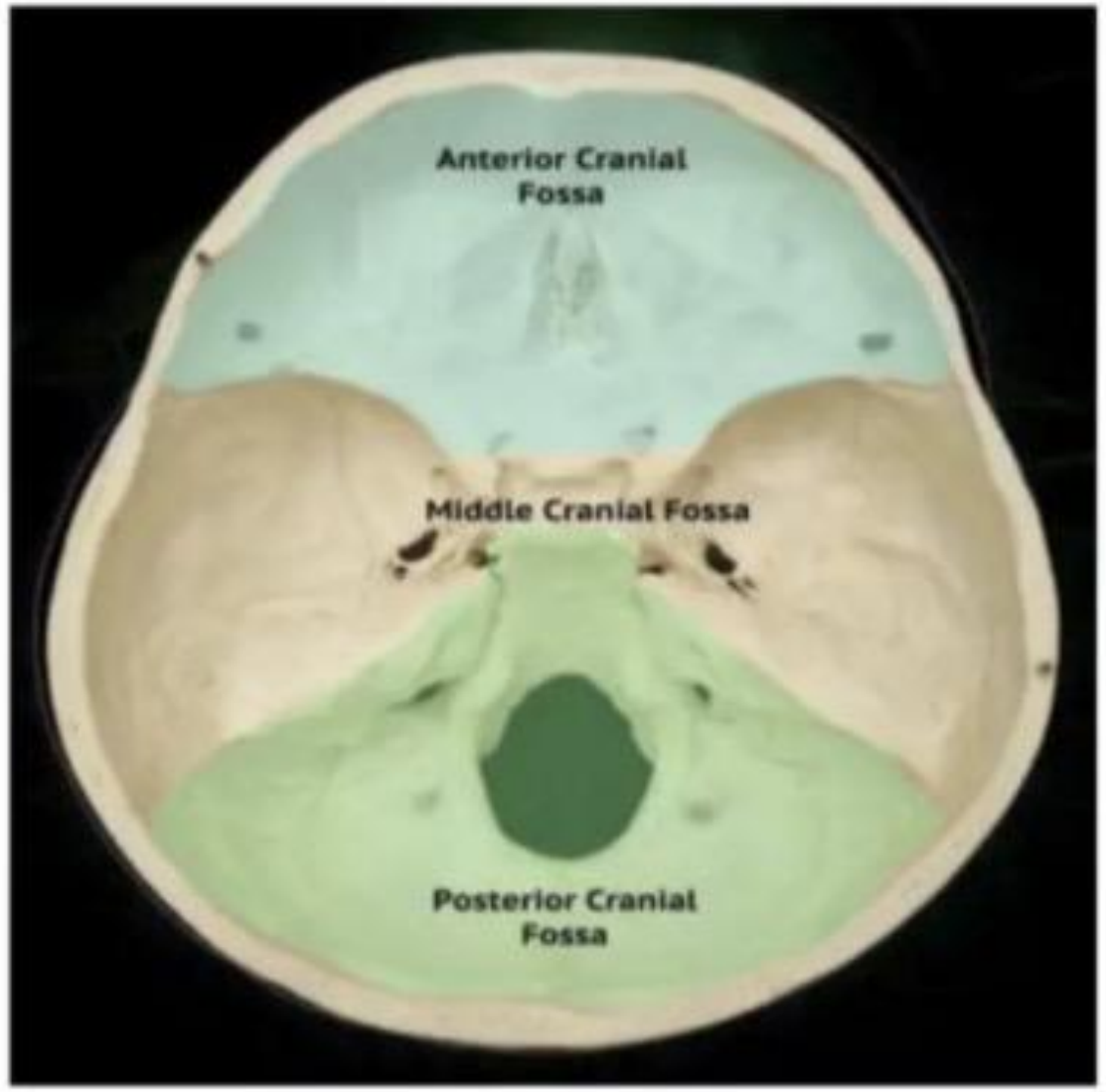
Anterior Cranial Fossa
Middle Cranial Fossa
Posterior Cranial Fossa

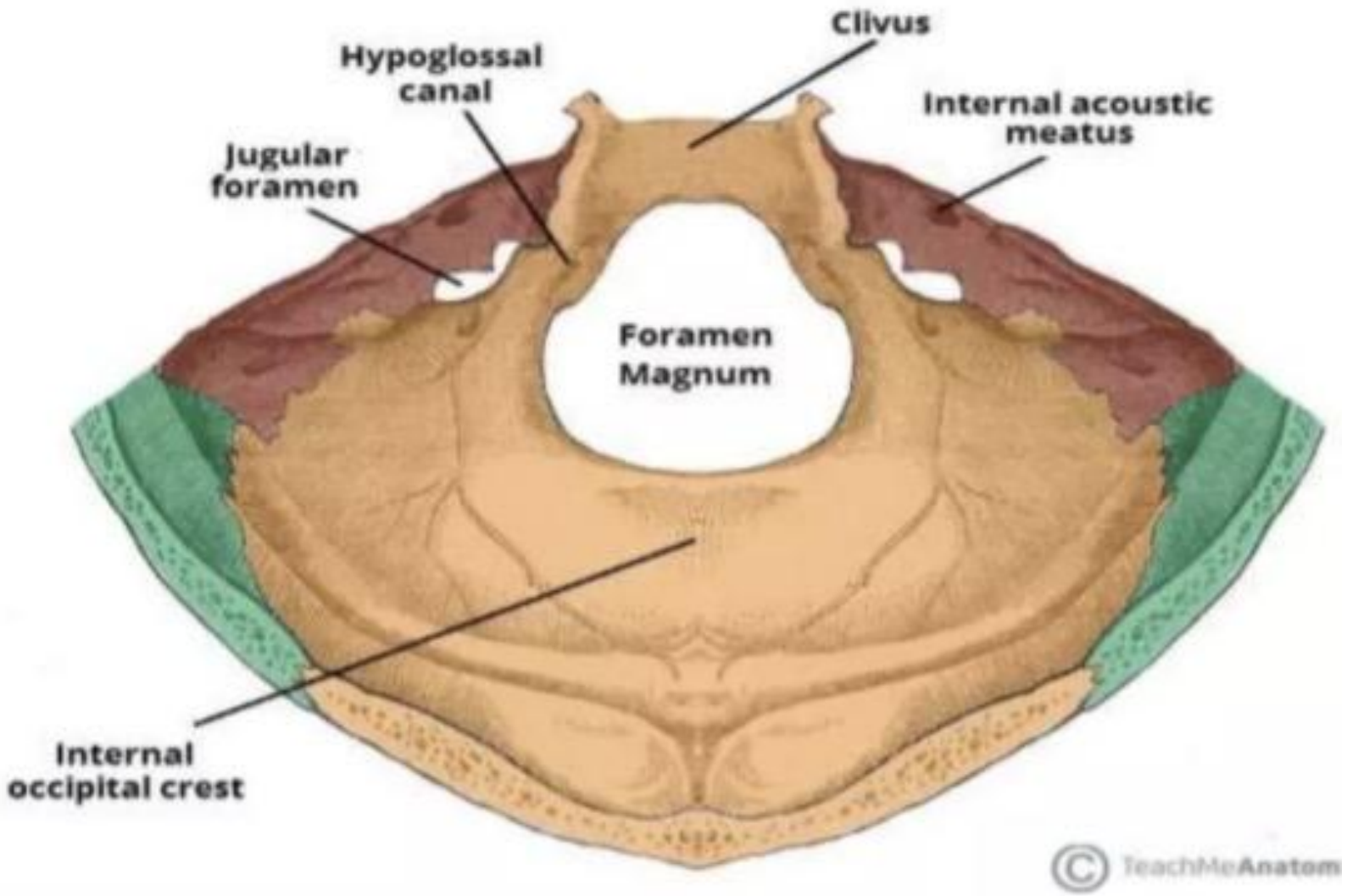
Clivus
Hypoglossal canal
Internal acoustic meatus
Jugular foramen
Foramen Magnum
Internal occipital crest
© TeachMeAnatom

- Anteriorly : Clivus, petrous part of temporal bone
- Posteriorly : Occipital bone
- Laterally : Squamous and mastoid part of the temporal bone
- Superiorly : Tentorium cerebelli
- Inferiorly : Foramen magnum

Indications of posterior fossa craniotomy :

Primary tumors are more common in children→Medulloblastoma

→Astrocytoma

→Ependymoma

Adults→Acoustic neuroma

→Meningioma

→Glioma

→Schwannoma

→Metastatic

- **Vascular lesions**→Aneurysm of basilar artery, posterior cerebellar artery.
- **Cranial nerve compression**
- **Congenital malformation:-**

  Dandy walker

  Arnold-Chiari malformation.

- **Hemorrhage**

SIGNS AND SYMPTOMS:

- Based on the location of the lesion.
- Rate of development.
- Impact on CSF, ICP.

Focal deficits d/t cranial nerve dysfunction:

- Ocular palsy
- Nystagmus
- Dysphagia

Cerebellar signs:

- Ataxia
- Tremor
- Motor incoordination.

Irregular respiratory pattern.

Sensory motor deficit.

ANAESTHETIC CONSIDERATION

- Preoperative Evaluation
- Monitoring
- Positioning
- Anaesthetic Technique
- Post Operative Management

Preanesthetic evaluation:

- Detailed medical history & examination
- Airway examination
- Neurological status:
  - Current & prior neurological deficit
  - Sign & symptoms of increased ICP.
  - History of seizure.
- Cardiopulmonary status

Investigations:

- CBC
- Blood grouping
- RFT
- LFT
- PT/INR
- RBS
- Viral Markers
- ECG
- chest x-ray.
- 2D-Echocardiography(if required)

MONITORING

- Standard ASA Monitoring
    - ECG
    - Pulse oximetry
    - NIBP
    - Capnography
    - Temperature
- Central venous catheterisation
- Arterial BP Monitoring
- Neuromuscular Monitoring

Goals of monitoring

- Adequate CNS perfusion
- Maintain cardiovascular stability
- Detect and treat Venous Air Embolism

Medications:

- Antiseizure medication- take the usual dose in the morning of surgery.
- Stop Anticoagulants prior to surgery
- Corticosteroids - take the usual dose in the morning of surgery.

Induction:

- Goal- maintain hemodynamic stability and cerebral perfusion pressure.
- Avoid rise in ICP.
- I.V. agents- Propofol, barbiturate
- Etomidate should be avoided as increases PONV and suppresses adrenal medulla.
- Lidocaine 1-1.5mg/kg to blunt laryngoscopy response
- Ketamine increases ICP so avoid.
- Opioids- Fentanyl, Remifentanil

Maintenance:

- Balanced inhalational→ low dose of potent inhalational + opioids.
- Total intravenous anesthesia- Opioid + propofol
- Inhalational agent:

❖ **1 MAC-** Decreases Cerebral Metabolic Rate & do not- abolish coupling→Increase in ICP is minimal (sevoflurane is best agent.)

❖ **>1 MAC** - Decreases CMR and abolish coupling which leads to increase in CBF and ICP increases.

- **N2O-** If alone leads to increase in ICP and CBF →sympathomimetic.
- Neuromuscular blocking agents

- **Hemodynamic management:**

Goal of intraoperative blood pressure-

MAP- ICP = CPP

Normal ICP - 5-10 mm hg

Normal CPP- 65-80 mm hg.

To maintain this CPP, MAP needs to be between 75-90 mm ng.

- **IV Fluids:-** Isotonic- plasmalyte

  Positive fluid balance- cerebral edema

  Negative fluid balance- vasospasm

- **Ventilation:**

  PaCO2- normocarbia

  Hypercarbia- increased ICP and causes cerebral edema.

  Hypocarbia- vasospasm

Brain relaxation:

- Required to improve surgical exposure & to avoid ischemia.
- Technique-

❖ Administer diuretics

❖ Start osmotherapy- Mannitol 0.5-1 gm/kg

❖ Glucocorticosteroid- 8 mg dexamethasone

❖ Hyperventilation

❖ Elevation of the patient's head.

POSITIONING

Patient can be operated in any of the following positions, depending on site of lesion

- Sitting Position
- Prone Position
- Park - Bench / Modified Lateral Position
- Supine Position

SITTING POSITION

- Patient head secured in a three pin head holder.
- Bony prominences are padded
- Legs placed in thigh high compression stockings to limit pooling of blood
- Elbows supported by pillows to avoid contact with table or stretch on brachial plexus
- Maintain 1 inch space between the chin and chest to prevent cervical cord stretching and obstruction of venous drainage

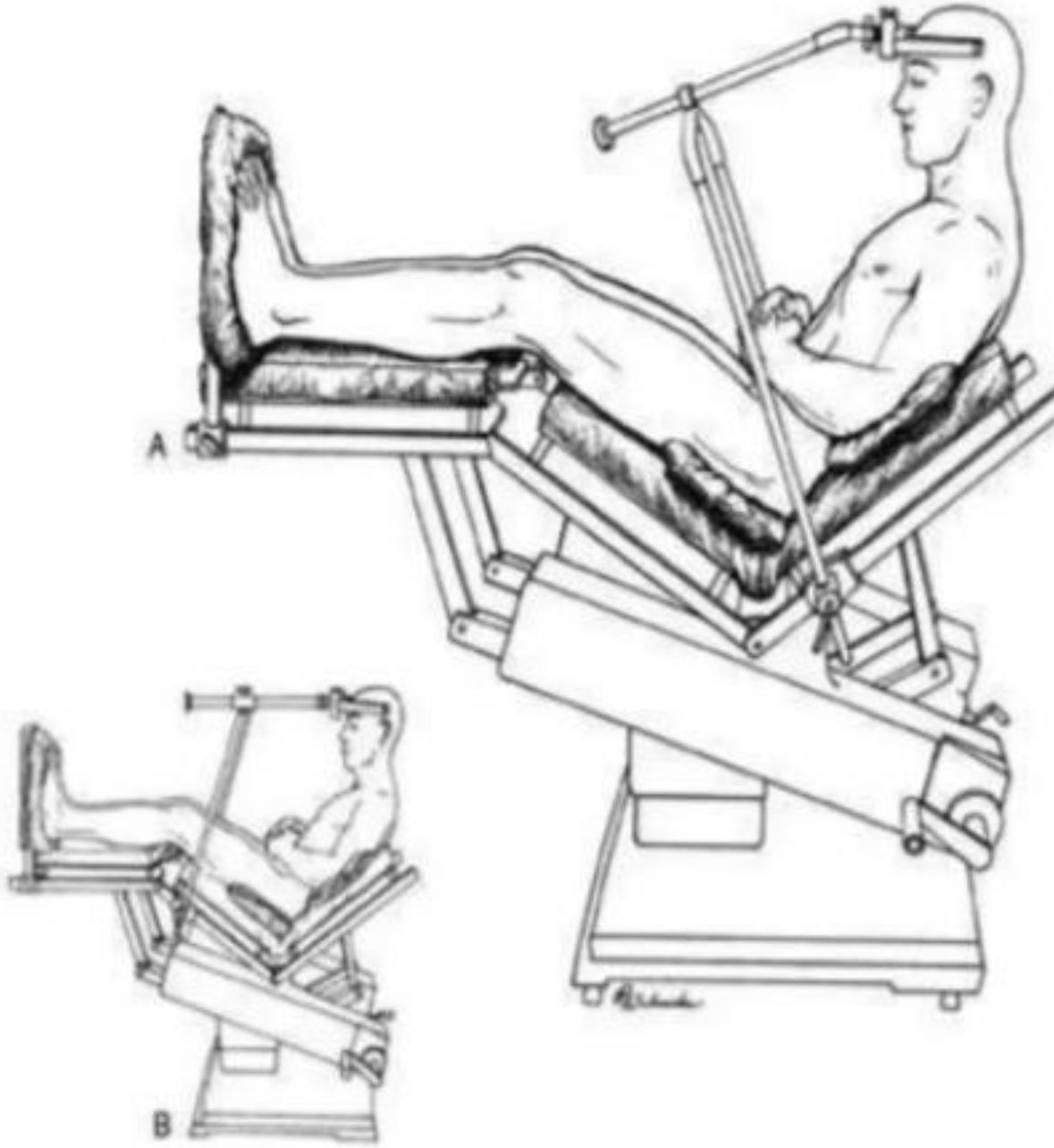

Semirecumbent position with back elevated at 60 and legs elevated with knee flexed. Arms remain on the side.

ADVANTAGES

- Better venous and CSF drainage
- Decreased blood loss
- Better surgical exposure, less tissue retraction, less cranial nerve damage and more complete resection of tumor possible.
- Increased access to ETT
- Access to extremities for monitoring fluid or blood administration

CONTRAINDICATION

- Right to left shunt
- Impaired cardiac function
- Degenerative diseases of cervical spine

COMPLICATIONS :

- Venous air embolism
- Pneumocephalus-May be worsened by NO diffusion after dural closure
- Macroglossia
- Spinal cord injury from neck flexion - quadriplegia
- Pressure areas: Knees,buttocks, Arms
- Surgical stimulation of the pons, medulla, and cranial nerve nuclei →hypotension, hypertension, bradycardia, tachycardia and arrhythmia.
- Peripheral nerve injury

PRONE POSITION

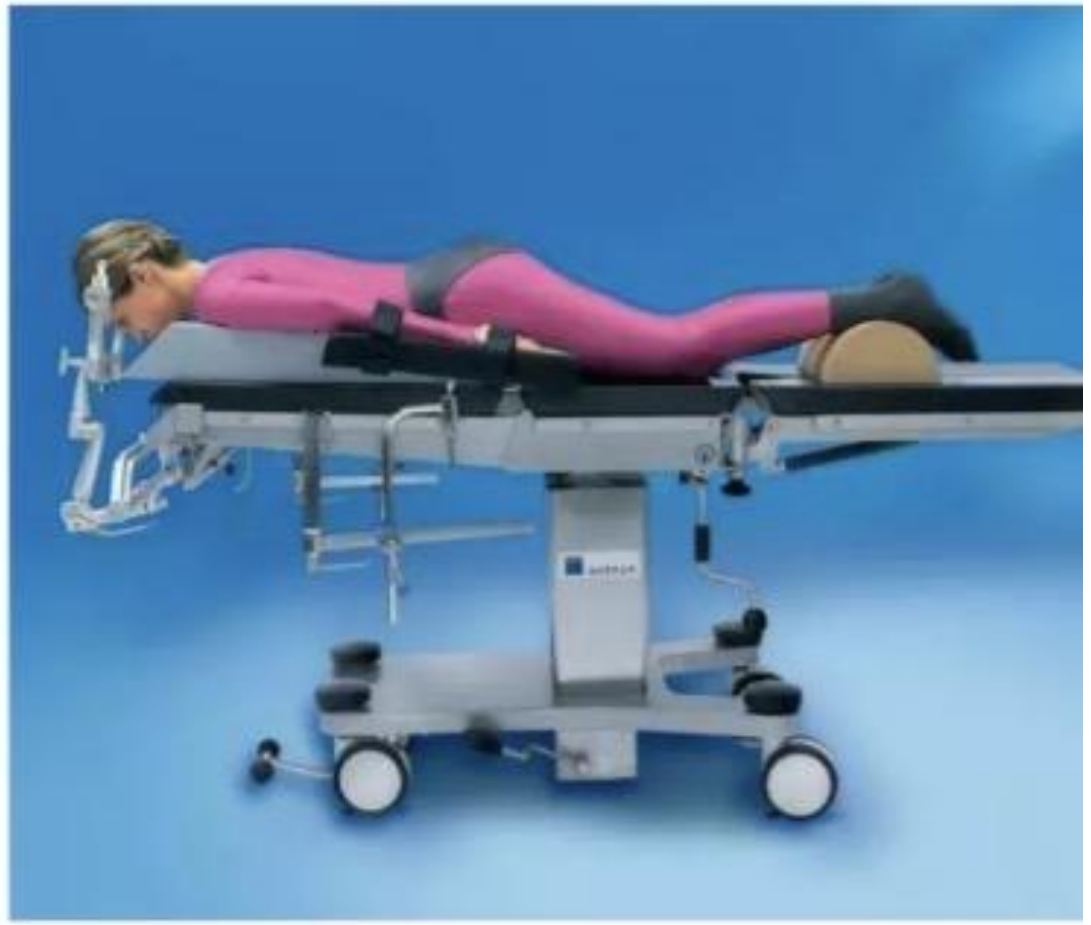

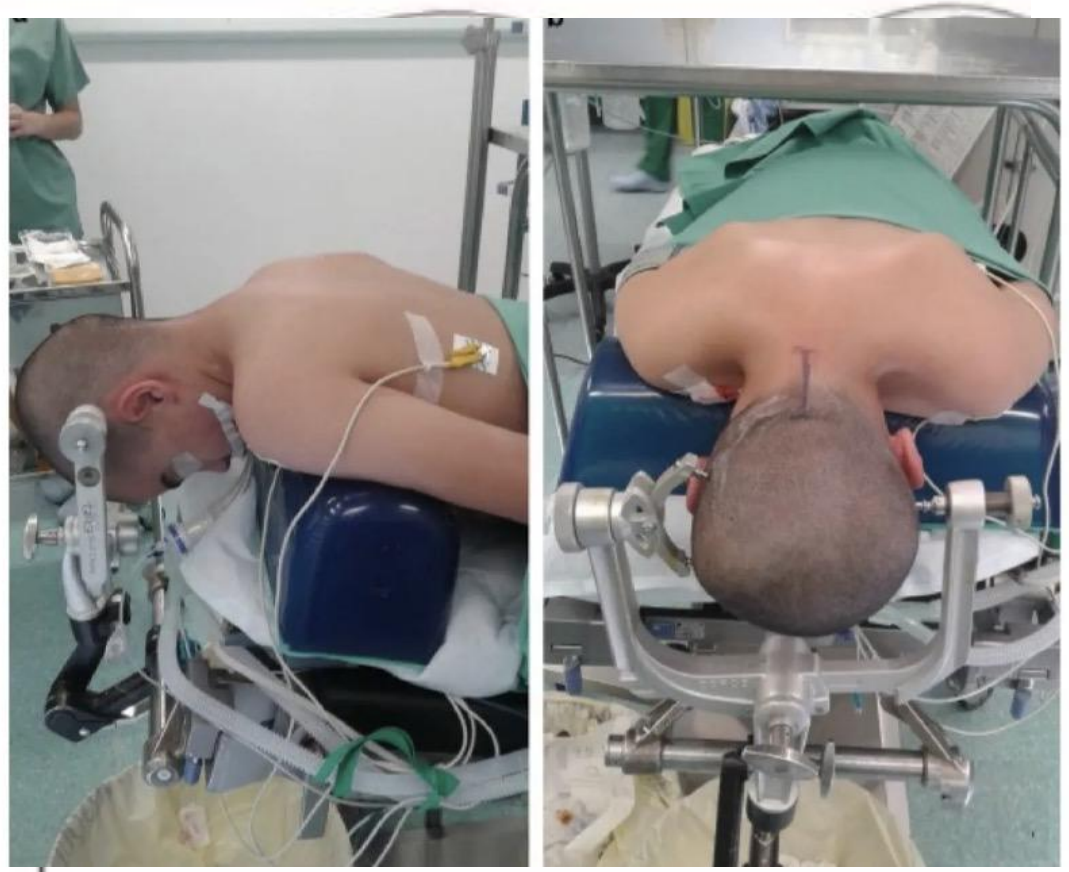

- Patients head elevated to decrease venous bleeding
- Face compression is prevented by keeping head elevated and shoulders at or above the edge of the operating table
- Lower incidence of VAE

- Disadvantages :
  - Surgical field is not as clear as in sitting
  - Eye compression can produce blindness from retinal artery thrombosis – Post Operative Visual Loss (POVL)
  - Conjunctival edema.
  - Venous pooling in the lower extremities can impair venous return
  - Abdominal pressure : impaired ventilation and increased IVC obstruction

Lateral Or Park Bench Position

- Can be used for access to the post parietal & occipital lobes & lat. post fossa, including tumors at the cerebellopntine angle & aneurysms of the vertebral & basilar arteries.

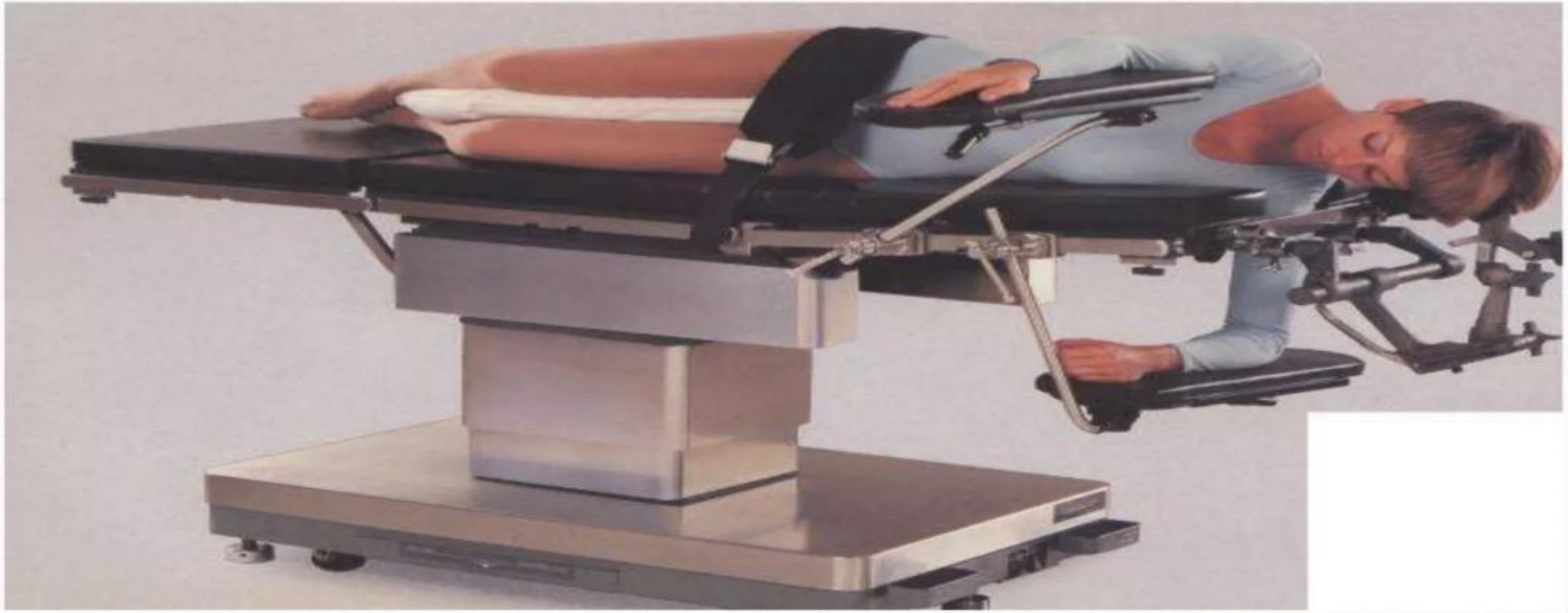

SUPINE POSITION

- Acoustic neuroma and cerebellopontine angle tumours can also be opera the supine position with the head turned to the opposite side

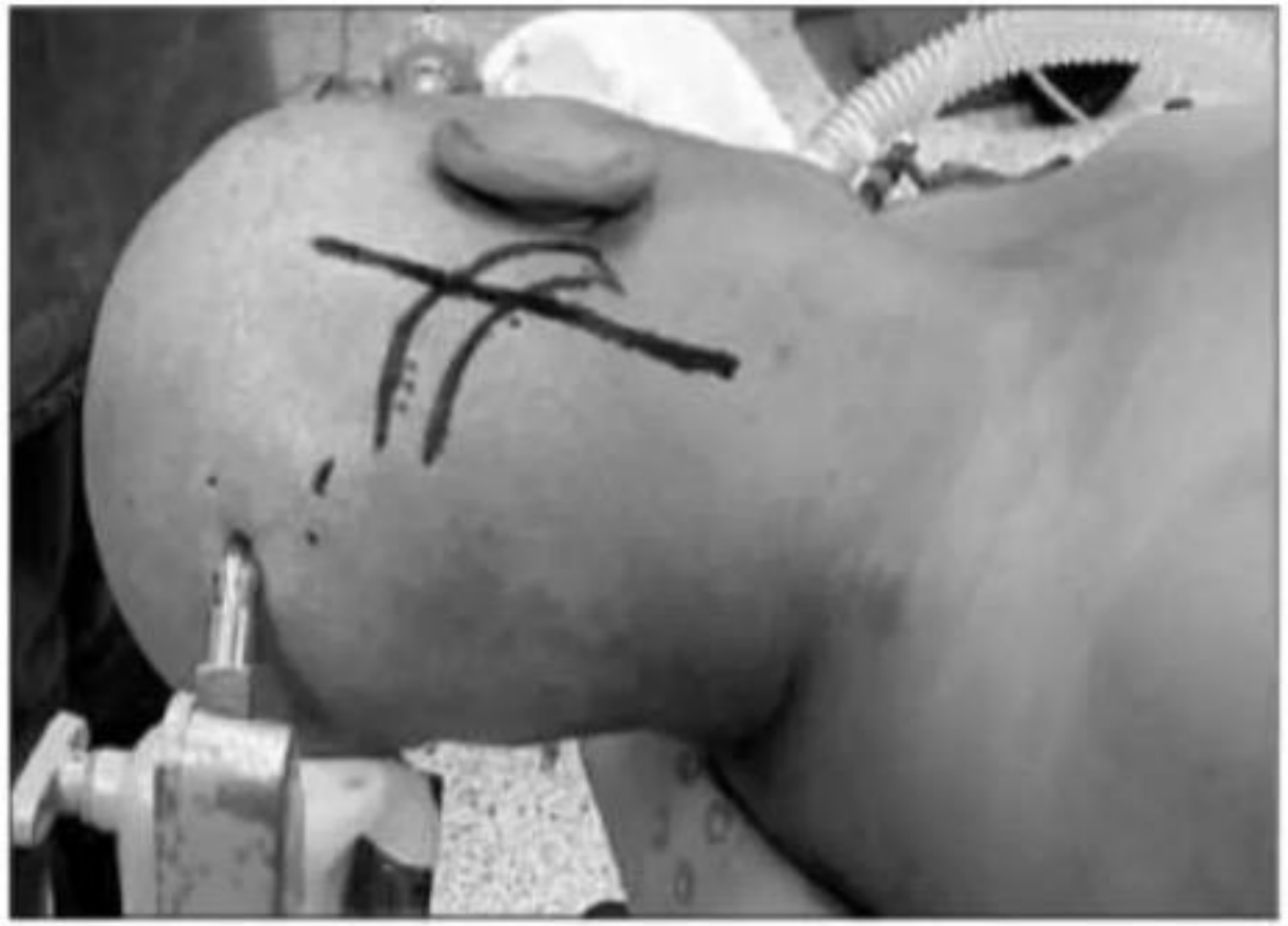

Fig 1. Dorsal decubitus (mastoid) position.

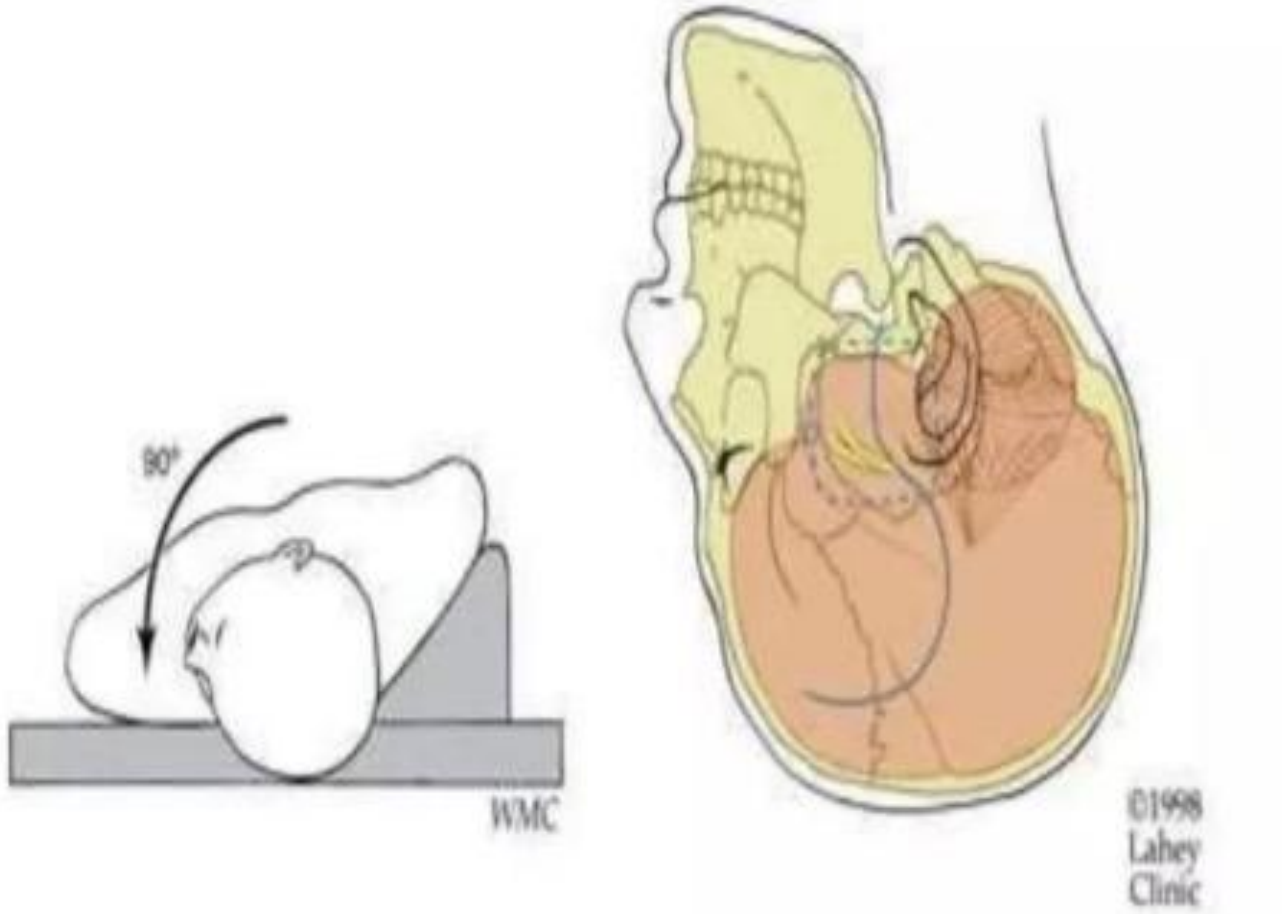
90°
WMC
©1998
Lahey
Clinic

EMERGENCE :

- Patients undergoing elective surgery can be extubated at end of procedure→provided ventilation and neurological function is adequate.
- Patients who remain intubated should be sedated and paralysed to avoid agitation
- Extubation should be smooth.
- Awakening helps in neurological assessment

POST OPERATIVE CARE

- Post Operative Ventilation
- Airway edema after prolonged prone positioning and tongue swelling after the sitting position.
- Postoperative hypertension should be carefully managed to avoid bleeding complications.
- Postoperative nausea and vomiting (PONV) and pain are important considerations after posterior fossa surgery.

VENOUS AIR EMBOLISM

- Venous air embolism is the entry of air into the venous circulation through an open vein when venous pressure is lower than atmospheric pressure, resulting in air transport to the right heart and pulmonary vasculature.
- Small amount is filtered
- >/=20-30 ml of air→ hemodynamic instability

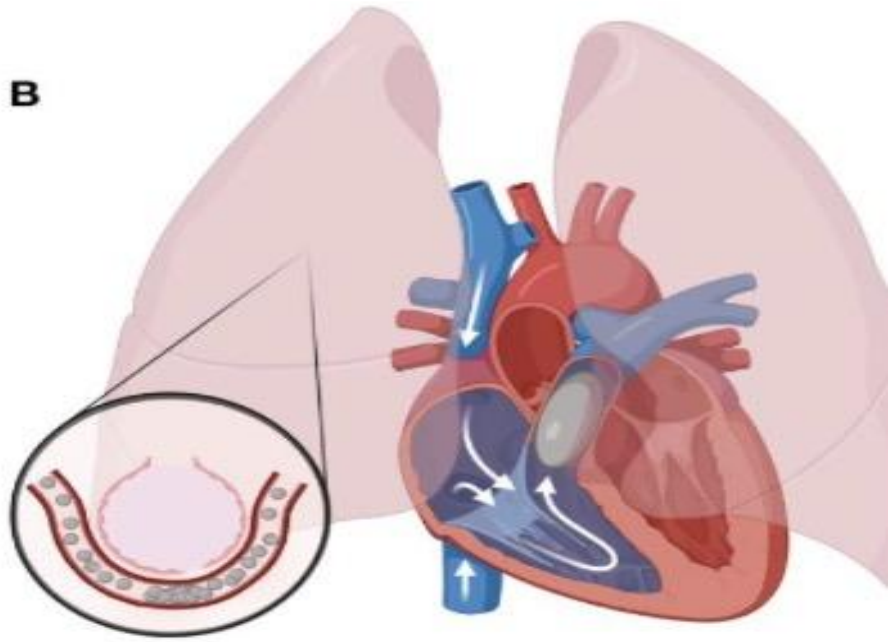

Monitoring:

- Most sensitive method→Transesophageal echocardiography
  Detects air bubbles as small as 0.25 mL
- ETCO2 monitoring→ sudden decrease suggest embolism.
- Cardiac signs:- Decrease Cardiac output, tachycardia , Hypotension ,Decrease BP, "mill wheel" murmur
- Sudden decrease in SPO2
- Arrhythmias

Immediate management

1. Inform surgeon immediately.Stop the Surgery
2. Stop further air entry; flood surgical field with saline where appropriate.
3. Administer 100% oxygen.
4. Stop nitrous oxide (N_2O), if being used.
5. Support circulation with IV fluids and vasopressors as required.
6. Aspirate air through an appropriately positioned central venous catheter, if available.
7. CPR if cardiac arrest occurs.

PNEUMOCEPHALUS

- Sitting position increases risk of pneumocephalus
- Air in entrapped on the surface of brain and ventricles
- Expansion after dural closure can cause compression of brain tissue
- Post operative delayed awakening and headache, vomiting.
- CT scan confirms the diagnosis and localization
- Treatment - twist drill aspiration of air through burr holes on either side of the vertex.
- If untreated Brain herniation and mortality.

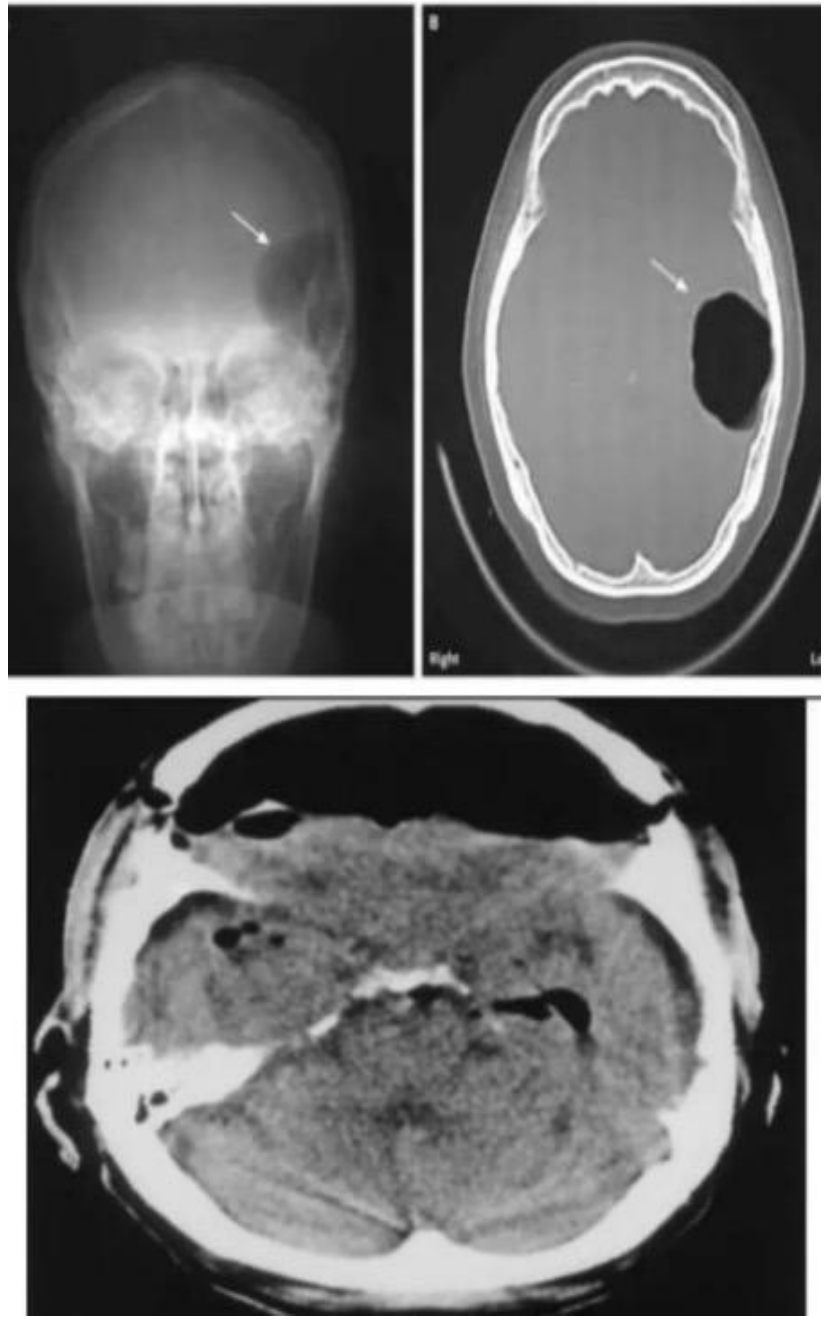

BRAINSTEM AND CRANIAL NERVE INJURY

- Hypertension results from stimulation of Periventricular Gray Matter,RAS
- Bradycardia results from vagus stimulation,
- Hypotension can results from pontine or medullary compression.
- Arrhythmias can occur from brain stem stimulation.

Thank you